

Vasculitis resulting from a superficial femoral artery angioplasty with a paclitaxel-eluting balloon

Shannon D. Thomas, FRACS,^a Robert R. A. McDonald, FACD,^{b,c} and Ramon L. Varcoe, MS, FRACS,^{a,d,e}
Sydney, New South Wales, Australia

Drug-eluting balloons (DEBs) coated with the antiproliferative agent paclitaxel may improve primary patency by reducing recurrent luminal stenosis. A proportion of the active drug and excipient coating are known to embolize distally, but until now, there have been no reports of adverse events resulting from their use. We report an unusual case of a painful nodular, biopsy specimen-proven vasculitic rash that afflicted the ipsilateral lower limb of a patient after superficial femoral artery treatment with a DEB. This adverse event may have implications for the use of DEB in this and other vascular territories. (*J Vasc Surg* 2014;59:520-3.)

Drug-eluting balloons (DEBs) are effective at reducing intimal hyperplasia after angioplasty of the superficial femoral artery, infrapopliteal circulation, and arteriovenous fistulas.¹⁻⁴ As a tool to both prevent and treat restenosis, DEBs are being applied to an ever-broader variety of vascular territories, including the carotid and coronary arteries.⁵⁻⁷ Until now, there have been no reports of target organ vasculitic, allergic, or hypersensitivity reactions with the use of this device.

CASE REPORT

A 72-year-old woman presented to our institution with a progressive 1-month history of severely restrictive recurrent left leg claudication. Before presentation, her left leg had been asymptomatic for 9 months after undergoing bare-metal stent revascularization of the midsuperficial femoral artery. Examination revealed palpable bilateral femoral pulses but absent popliteal and pedal pulses on the symptomatic side. Her limbs showed no evidence of venous disease, rash, or ulceration. Arterial duplex ultrasound imaging revealed a critical in-stent stenosis of the previously placed superficial femoral artery stent (peak systolic velocity, 438 cm/s) with a reduced ankle-brachial pressure index of 0.75.

She had a history of dyslipidemia and hypertension, with known allergies to rosuvastatin (skin rash) and ezetimibe (skin rash). She was receiving lipid-lowering (gemfibrozil), antihypertensive (ramipril), and dual-antiplatelet (clopidogrel and aspirin) medications.

From the Department of Surgery, Prince of Wales Hospital^a; Sky Blue Dermatology^b; the Department of Dermatology, St. Vincent's Hospital^c; the Faculty of Medicine, University of New South Wales^d; and The Vascular Institute, Prince of Wales Hospital.^e

Author conflict of interest: Dr Thomas has been given an educational grant by Medtronic Endovascular.

Reprint requests: Dr Ramon L. Varcoe, Prince of Wales Private Hospital, Barker St, Ste 8 Level 7, Randwick, NSW 2031, Australia (e-mail: r.varcoe@unsw.edu.au).

The editors and reviewers of this article have no relevant financial relationships to disclose per the JVS policy that requires reviewers to decline review of any manuscript for which they may have a conflict of interest.

0741-5214/\$36.00

Copyright © 2014 by the Society for Vascular Surgery. Published by Elsevier Inc. All rights reserved.

<http://dx.doi.org/10.1016/j.jvs.2013.03.013>

The patient underwent an elective superficial femoral artery angioplasty procedure. The lesion was approached through an atraumatic antegrade left common femoral artery puncture and placement of a 6F Britetip sheath (Cordis, Johnson & Johnson, Warren, NJ). After predilatation with a 6- × 100-mm conventional Fox Cross balloon catheter (Abbott Vascular, Abbott Park, Ill), a 6- × 120-mm In.Pact Admiral DEB, with paclitaxel coating (3 µg/mm²; Invatec, Medtronic, Minn) was inflated according to the manufacturer's recommendation. Completion angiography demonstrated a pleasing angiographic result, free of dissection, recoil, or thrombus. No evidence of distal embolization was apparent on runoff angiography. There were strong popliteal and pedal pulses after the procedure, and she was discharged the next day with no evidence of rash.

She presented 1 week after the procedure after developing a mildly painful rash, prominent on the distal aspect of her left lower limb from the lower thigh to the ankle but which spared the foot (Fig 1). The rash consisted of nonblanching, small erythematous nodules that were nonhemorrhagic. No additional cutaneous lesions were noted on her body.

Analysis of a punch biopsy specimen showed epidermal and upper dermal edema with an intense inflammation of the medium-sized vessels in the superficial subcutaneous fat. Prominent fibrin deposition and a mononuclear infiltrate within the arteriole walls was noted, as well as thrombosis of surrounding small vessels and a diffuse infiltrate containing neutrophils and eosinophils (Fig 2). The result of a vasculitic blood screen was negative for the presence of an underlying systemic vasculitis syndrome. In view of the histopathologic analysis, the distribution of the rash, and its temporal relationship to the procedure, a diagnosis of vasculitis secondary to the DEB was made.

The patient was treated with a short course of oral steroids and emulsifying ointment. During the next 12 weeks, the rash continued to improve but did not completely resolve. Pain and itch have since abated, and no serious adverse event has eventuated at 4 months of follow-up.

DISCUSSION

The current commercially available DEBs all use the antiproliferative drug paclitaxel to prevent or treat restenosis after the successful dilatation of an arterial stenosis. This

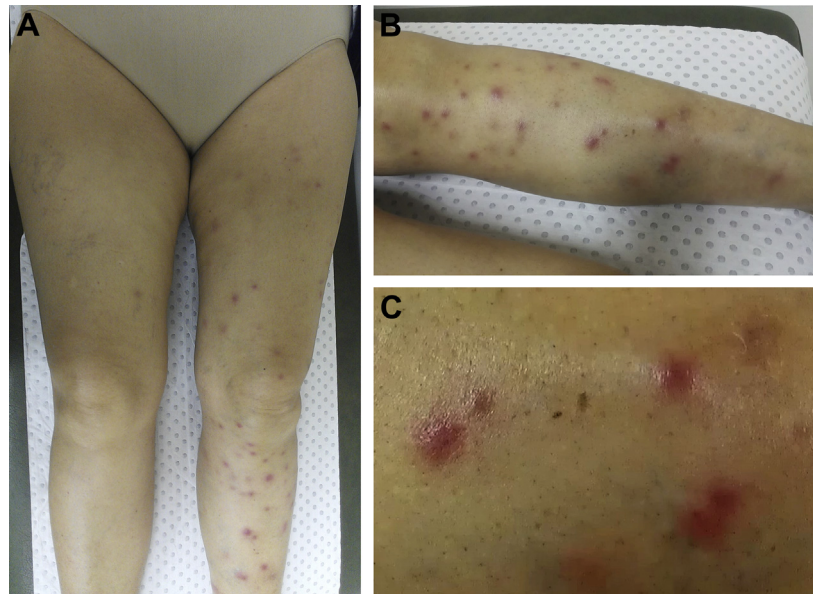


Fig 1. A, Vasculitic rash confined to the left leg after therapy with a paclitaxel-eluting balloon. B, Nodular, erythematous macules in the distribution of the superficial femoral artery treated with a paclitaxel-eluting balloon. C, Magnified view of the vasculitic rash on the lower leg, demonstrating nonblanching, nonhemorrhagic, nodular, erythematous macules.

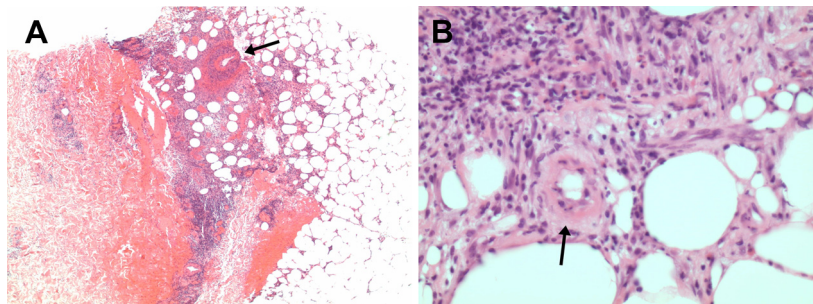


Fig 2. A, Photomicrograph (original magnification, $\times 40$) of histologic specimen demonstrates inflammation and fibrin within the wall of an arteriole within the subcutaneous fat (arrow). B, Photomicrograph (original magnification, $\times 400$) shows mixed cellular infiltrate comprising lymphocytes, neutrophils, and eosinophils in the subcutis and a thrombosed small vessel with fibrin within its wall (arrow).

highly lipophilic drug⁸ inhibits the proliferation of vascular smooth muscle cells that would otherwise accumulate within the neointima and form a hyperplastic restenotic lesion.⁹ A variety of excipient carrier molecules have been used to facilitate paclitaxel delivery to the target lesion, including urea, iopromide, butyryl-tri-hexyl citrate, and shellolic acid.¹⁰ During balloon inflation, these drugs are liberated, some implanting as drug reservoirs into the blood vessel wall to exert their effect locally, whereas other clumps are released downstream in a phenomena known as “particulate embolization.” This phenomenon was studied by Heilmann et al¹¹ in a porcine model, in which they demonstrated that $>50\%$ of the drug coating washes off into the distal circulation. In that study, the type of excipient and method of balloon coating (drug-coated or wrap-ped) affected the efficiency of drug transfer. In human

studies, Freyhardt et al¹² demonstrated paclitaxel within the systemic circulation after lower limb DEB angioplasty. There is concern about what long-term effect this shower of drug into the end organ may have; however to date, there have been no published reports of allergy or vasculitic reactions. This has been reassuring for all who use these devices and has resulted in their broad application to include vascular territories where the end organ may be less forgiving than the lower limb.^{10,13}

We propose that our patient’s vasculitic rash was related to particulate embolization of the drug coatings on the balloon, of which paclitaxel and urea feature most prominently. In support of this, we note that the rash was present only in the vascular territory fed by the treated superficial femoral artery and appeared 5 days after that treatment. Close physical examination of her skin and

a biochemical analysis of her organ parameters revealed no evidence of allergic or vasculitic reaction in other vascular beds, confirming that the process was isolated to her left leg. It is likely that a reaction to the oral medications, intravenous sedatives, analgesics, and local anesthetics used in the periprocedural period would have resulted in wider evidence of a systemic reaction.

Theoretically, an inflammatory contaminant introduced through the working sheath could have also caused such a vasculitic reaction; however, no such contamination occurred within the sterile operating theater environment where the procedure took place. The patient did not have allergies to docetaxel¹⁴ or hazelnuts,¹⁵ to which cross-allergenicity to paclitaxel have been described.

Finally, atheroembolism was considered to have been unlikely given that smooth in-stent restenosis was the lesion targeted by angioplasty and the distal limb arteries were patent when examined at the completion of the procedure. Paclitaxel hypersensitivity rashes have been previously described with variable features, at times similar to the rash in this patient.¹⁶ Thus, we have a plausible mechanism, a strong temporal relationship, and absence of an alternative cause for her clinical syndrome.

To date, the published experience with DEBs has been limited by small numbers and short follow-up. There are no reports of end-organ or distal vascular bed lesions as a result of deposition of the antiproliferative drug and excipient. Stent hypersensitivities in the coronary literature have been reported and investigated.¹⁷ Nebeker et al¹⁸ reviewed all drug-eluting stent hypersensitivities reported to the Food and Drug Administration between 2003 and 2004, detecting stents in 17 patients that caused a hypersensitivity reaction resulting in eosinophilic inflammation, thrombosis, or lack of intimal healing. Explanted samples demonstrated stent thrombosis and vascular ectasia due to an eosinophilic inflammation that resulted in a lack of intimal healing. Distal vascular bed lesions, such as the one in our patient, have not been demonstrated.

Generational development of DEBs has seen evolving improvements in target lesion drug delivery determined largely by the carrier excipient molecule used. These carrier molecules are critical in determining the volume of drugs delivered to and retained within the target lesion, as well as the proportion of drugs lost downstream.¹⁹ Newer-generation DEBs promise to improve drug delivery and vessel wall retention while reducing particulate embolization. These excipient variations may avoid the distal vascular injuries seen in this patient.

As a first report of vasculitis from a DEB, this is an isolated event by definition. However, in the context of a new technology with little published experience, it may be considered a warning to users at a time when there is uncertainty about the incidence of the event, but many are seeking to broaden the application of DEBs into new vascular territories. Our patient is progressing toward a full recovery; however, if this DEB had been used in her carotid, renal, or mesenteric circulation, such a vasculitis might have resulted in a major serious adverse event.

CONCLUSIONS

We present here a patient with vasculitic rash of the lower limb after treatment with a DEB, thought to be a reaction to particulate embolization of paclitaxel and urea. Although DEBs have been shown to improve patency in the treatment of arterial occlusive disease, hypersensitivity reactions with serious clinical consequences may occur and warrant careful consideration.

We acknowledge Dr Geoff O'Brien, of Healthscope Pathology, for his assistance with the histopathologic analysis.

REFERENCES

- Schmidt A, Piorkowski M, Werner M, Ulrich M, Bausback Y, Bräunlich S, et al. First experience with drug-eluting balloons in infrapopliteal arteries: restenosis rate and clinical outcome. *J Am Coll Cardiol* 2011;58:1105-9.
- Tepe G, Zeller T, Albrecht T, Heller S, Schwarzwälder U, Beregi JP, et al. Local delivery of paclitaxel to inhibit restenosis during angioplasty of the leg. *N Engl J Med* 2008;358:689-99.
- Werk M, Langner S, Reinkensmeier B, Boettcher HF, Tepe G, Dietz U, et al. Inhibition of restenosis in femoropopliteal arteries: paclitaxel-coated versus uncoated balloon: femoral paclitaxel randomized pilot trial. *Circulation* 2008;118:1358-65.
- Katsanos K, Karnabatidis D, Kitrou P, Spiliopoulos S, Christeas N, Siablis D. Paclitaxel-coated balloon angioplasty vs. plain balloon dilation for the treatment of failing dialysis access: 6-month interim results from a prospective randomized controlled trial. *J Endovasc Ther* 2012;19:263-72.
- Cortese B, Micheli A, Picchi A, Coppolaro A, Bandinelli L, Severi S, et al. Paclitaxel-coated balloon versus drug-eluting stent during PCI of small coronary vessels, a prospective randomised clinical trial. The PICCOLETO study. *Heart* 2010;96:1291-6.
- Liistro F, Porto I, Grotti S, Ventoruzzo G, Vergallo R, Bellandi G, et al. Drug-eluting balloon angioplasty for carotid in-stent restenosis. *J Endovasc Ther* 2012;19:729-33.
- Montorsi P, Galli S, Ravagnani PM, Rabattoni D, Fabbicchi F, Lualdi A, et al. Drug-eluting balloon for treatment of in-stent restenosis after carotid artery stenting: preliminary report. *J Endovasc Ther* 2012;19:734-42.
- Loh JP, Waksman R. Paclitaxel drug-coated balloons: a review of current status and emerging applications in native coronary artery de novo lesions. *JACC Cardiovasc Interv* 2012;5:1001-12.
- Newby AC, Zaltsman AB. Molecular mechanisms in intimal hyperplasia. *J Pathol* 2000;190:300-9.
- Scheller B, Ehrlein C, Bocksch W, Rutsch W, Haghi D, Dietz U, et al. Treatment of coronary in-stent restenosis with a paclitaxel-coated balloon catheter. *N Engl J Med* 2006;355:2113-24.
- Heilmann T, Richter C, Noack H, Post S, Mahnkopf D, Figulla H. Drug release profiles of different drug-coated balloon platforms. *Eur Cardiol* 2010;6:40-4.
- Freyhardt P, Zeller T, Kröncke TJ, Schwarzwälder U, Schreiter NF, Stiepani H, et al. Plasma levels following application of paclitaxel-coated balloon catheters in patients with stenotic or occluded femoropopliteal arteries. *Rofo* 2011;183:448-55.
- Scheller B, Speck U, Abramjuk C, Bernhardt U, Böhm M, Nickenig G. Paclitaxel balloon coating, a novel method for prevention and therapy of restenosis. *Circulation* 2004;110:810-4.
- Dizon DS, Schwartz J, Rojan A, Miller J, Pires L, Disilvestro P, et al. Cross-sensitivity between paclitaxel and docetaxel in a women's cancers program. *Gynecol Oncol* 2006;100:149-51.
- Bukacel DG, Bander R, Ibrahim RB. Cross-reactivity between paclitaxel and hazelnut: a case report. *J Oncol Pharm Pract* 2007;13:53-5.
- Beri R, Rosen FR, Pacini MJ, Desai SR. Severe dermatologic reactions at multiple sites after paclitaxel administration. *Ann Pharmacother* 2004;38:238-41.

17. Kataoka Y, Kapadia SR, Puri R, Harvey JE, Martin J, Nicholls SJ, et al. Suspected hypersensitivity reaction following drug-eluting stent implantation. Novel insights with optical coherence tomography. *JACC Cardiovasc Interv* 2012;5:e21-3.
18. Nebeker JR, Virmani R, Bennett CL, Hoffman JM, Samore MH, Alvarez J, et al. Hypersensitivity cases associated with drug-eluting coronary stents: a review of available cases from the Research on Adverse Drug Events and Reports (RADAR) project. *J Am Coll Cardiol* 2006;47:175-81.
19. Waksman R, Pakala R. Drug-eluting balloon: the comeback kid? *Circulation Cardiovasc Interv* 2009;2:352-8.

Submitted Jan 24, 2013; accepted Mar 12, 2013.

CME Credit Available to JVS Readers

Readers can obtain CME credit by reading a selected article and correctly answering four multiple choice questions on the Journal Web site (www.jvascsurg.org). The CME article is identified in the Table of Contents of each issue. After correctly answering the questions and completing the evaluation, readers will be awarded one *AMA PRA Category 1 Credit*TM.